

**SAN LUIS OBISPO COUNTY  
SHERIFF-CORONER OFFICE  
1585 KANSAS AVE.  
SAN LUIS OBISPO, CA 93405**

**CORONER'S REPORT**

**FILE NO. 18091**

---

**DECEDENT:** Gatlin, Baylee Ybarra  
Age: 20 DOB: 4/24/97  
[REDACTED]

**RESIDENCE ADDRESS:** [REDACTED]

**NEXT OF KIN:** [REDACTED]

**LOCAL CONTACT:** [REDACTED]

**DATE/TIME OF DEATH:** 5/28/17 @ 0342 pronounced

**LOCATION OF DEATH:** Twin Cities Community Hospital  
1100 Las Tablas Rd  
Templeton, CA 93465

**REGULAR PHYSICIAN:** unknown

**MEDICAL HISTORY:** Refer to file

**AUTOPSY SURGEON:** Dr. Gary Walter, M.D.  
San Luis Obispo County Coroner's Office  
1585 Kansas Ave.  
San Luis Obispo, CA 93405

**CAUSE OF DEATH:** **Acute Lysergic Acid Diethylamide Toxicity**

**MANNER OF DEATH:** **Accident**

**LOCAL MORTUARY:** Ted Mayr Funeral Home  
3150 Loma Vista Rd  
Ventura, CA 93003  
805-643-9977

**INVESTIGATING AGENCY CASE#:** Monterey County Sheriff 17-2730

**ASSOCIATED CORONER'S CASE#:** 1705-04424

## INVESTIGATION

On 5/28/17 at 0402 hours Deputy Campos and Deputy Dugan were dispatched to this coroner's case. I responded to the hospital soon after. I assumed jurisdiction and investigation of the death of Baylee Gatlin pursuant to California Government Code 27491.

Deputies arrived at Twin Cities Community Hospital (TCCH) regarding a request for a coroner in regards to a 20 year old female that had passed away in the Emergency Department. Dr. Joe Robinson pronounced death at 0342 hours. The decedent was brought to the hospital from the Lightning in a Bottle Festival. The festival is held in Monterey County at Lake San Antonio. The event is an annual music festival. While in route to the hospital via American Medical Response ambulance, the decedent lost her vitals and CPR life-saving efforts were administered until the decedent's care was turned over to TCCH personnel.

The decedent had initially been tended to by festival staff. The decedent was tended to by festival staff for a possible bad reaction to narcotics. The decedent had an altered mental status and developed a high temperature. The decedent was then attended to by medical staff, and an ambulance was subsequently requested for transport to TCCH.

I later spoke with Monterey County Sheriff Detective Dycke, who had been assigned to investigate the incident. I learned from Dycke and acquaintances the events leading up to the ambulance transport. The decedent had attended the festival with friends. The decedent had camped at the location. It was reported the decedent had possibly taken LSD. The decedent had been seen by friends throughout the day leading up to her passing. The decedent had been seen dancing and was reported to be "altered." The decedent appeared to be overheating and was taken to the area where festival personnel tended to her. A friend had stated the decedent reportedly "accidentally" took a second hit of LSD. I was told the decedent had taken LSD in the past and was familiar with the narcotic. The decedent was taken to the "Zen Dome" which is a tent set up for "Psychedelic Harm Prevention" as a result of narcotics use.

I was told by hospital staff that the decedent had temperatures of 105 degrees prior to arrival at the hospital and 103 degrees while being treated in the hospital. I was advised that approximately 4800 ml of fluid was removed from the decedent's lungs at the hospital. Despite the best efforts from TCCH personnel, vitals were not able to be restored after one hour and 45 minutes of emergency care.

A search of the decedent's property at the hospital revealed suspected marijuana, gummy candies, and unknown capsule type pills. The items were sent to the Sheriff's Crime Laboratory for analysis. The gummy candy revealed the presence of LSD and the capsules revealed the presence of methamphetamine.

I later provided contact information for the decedent's friends at the festival to Dycke for investigative purposes.

I ordered an autopsy be performed on 5/31/17. Forensic Pathologist Dr. Walter examined the decedent at the Coroner's Office. I provided Dr. Walter with information about the incident and he reviewed the medical records I had obtained as of this date. Upon completion of the autopsy, Dr. Walter did not provide a cause of death. I later received the Final Autopsy Report, and Dr.

Coroner Case #18091

Decedent: Gatlin, Baylee Ybarra

Walter provided a cause of death as **Acute Lysergic Acid Diethylamide Toxicity**. For details refer to the Final Autopsy Report.

I requested TCCH hospital records, ambulance care reports, and investigative reports from Monterey County Sheriff's Office. After reviewing the records I incorporated them with this file.

I collected blood samples drawn by hospital staff during the decedent's time in the emergency room. I collected vitreous fluid at the coroner's office. The samples were sent to Central Valley Toxicology for analysis.

I received the toxicology report that had been completed on 6/2/17. Refer to the Toxicology Report for quantitative values.

### DISPOSITION OF PERSONAL PROPERTY

A cell phone, personal items including but not limited: jewelry, trinkets, stones, stickers, etc., birth control pills, a cut waist pack, and \$6 cash were booked for safekeeping. All items were photographed prior to booking. The decedent's clothing was provided to the mortuary.

### CLOSING STATEMENT

Based upon the investigation, I certified the manner of death as **Accident** and the cause of death as **Acute Lysergic Acid Diethylamide Toxicity**.

I completed and electronically signed the death certificate and amendment to the death certificate.

All medical information referred to in this report will not be released, as part of this report, because of both state and federal privacy statutes. These records will have to be obtained from the care provider.

Any law enforcement agency's report referred to in this report will not be released, as part of this report, and a copy of the report will have to be obtained from the law enforcement agency conducting the investigation.

Photographs will not be released pursuant to Code of Civil Procedure 129.



---

Rory Linn, Detective Coroner #1243

JW/1160/08-02-2017

**Decedent:**

GATLIN, Baylee Ybarra  
**Age:** 20 YEARS      **Sex:** Female

**Accession #:**

A17-000266

**Prosector:**

Gary A. Walter, M.D., Med. Dir

**Autopsy Location:**

San Luis Obispo County Coroner's Office

**Responsible Party:**

San Luis Obispo Coroner

**Expired Date:** 05/28/2017

**Expired Time:** 3:42AM

**Autopsy Date:** 05/31/2017

**Autopsy Time:** 9:30AM


**Reported Date:** 07/20/2017

**FINAL AUTOPSY REPORT**

**CAUSE OF DEATH:**

**ACUTE LYSERGIC ACID DIETHYLAMIDE TOXICITY (MINUTES)**

GAW/ima 05/31/2017



Gary A. Walter, M.D., Med. Dir

**TOXICOLOGY:**

**Specimen:** Hospital Blood (Lavender Top Vial and Blue Top Vial) and Vitreous Humor Samples

**Complete Drug Screen:** Lidocaine detected. Specific drug assay for Bath Salts, GHB, LSD, Psilocin, Synthetic Cannabinoids and U-47700 performed. No other common acidic, neutral or basic drugs detected. No Ethyl Alcohol detected.

- Lysergic Acid Diethylamide (LSD) by LCMS-MS = Positive
- "Bath Salts" by LCMS-TOF = Negative  
(Cathinone, Methcathinone, Methylone, Mephedrone, MDPV, and alpha-PVP)
- Gamma-Hydroxybutyrate (GHB) by GCMS = Negative
- Psilocin (metabolite of Psilocybin) and Synthetic Cannabinoids ("Spice") by LCMS-TOF = Negative
- U-47700 by LCMS-TOF = Negative

Buprenorphine = Negative

LSD in Hospital Lavender Top Tube = 0.22 ng/mL

LSD in Hospital blue top tube = 0.47 ng/mL

Lidocaine = 2.65 mg/L

Vitreous Urea Nitrogen = 41 mg/dL

Blood Lidocaine Ranges

Effective Level: (1 - 5 mg/L)

Potentially Toxic: (6 - 10 mg/L)

Blood Lysergic Ranges

Effective Level: (0.5 - 5 ng/mL)

Potentially Toxic: (1 ng/mL)

**GROSS FINDINGS:****INTRODUCTION:**

I performed an autopsy on a body identified as Baylee Ibarra Gatlin, age 20, **San Luis Obispo County Coroner's case (18091)** done at the San Luis Obispo County Coroner's Office in San Luis Obispo, California on May 31, 2017. The autopsy began at 0930 hours. Witnesses include Detective Rory Linn of the San Luis Obispo County Sheriff Coroner's Office. During the course of the autopsy, hospital admission blood was obtained for toxicologic examination. In addition, vitreous humor was taken for toxicology examination. From the anatomic findings and pertinent history, I ascribe the death to acute lysergic acid diethylamide toxicity (minutes).

**RECENT MEDICAL ARTIFACTS AT AUTOPSY:**

1. Endotracheal tube.
2. EKG pads, multiple.
3. Defibrillator pads (x2).
4. I.V., right antecubital fossa.
5. I.V., right groin.
6. Urinary catheter.
7. I.V., posterior right hand.

**IDENTIFYING MARKS:**

Tattoo, right upper back.

**EXTERNAL EXAMINATION:**

The body is that of a well-developed, well-nourished, Caucasoid female appearing consistent with recorded age of 20 years. The body is examined in the unembalmed state. There is mild rigor mortis and moderate predominantly posterior livor mortis. There is focal marbling of the skin of the right and left flank area, consistent with early decomposition. The hair is black and normal in amount and distribution for age. The eyes are unremarkable. The oral cavity is unremarkable. The nose, ears and neck are without gross abnormalities. The thorax is symmetrical and of normal anteroposterior diameter. There is an area of abrasion involving the mid sternal skin consistent with resuscitation efforts. The abdomen is flat and without gross abnormalities. The external genitalia are those of a normal adult female. The extremities appear normal in development and structure and are without edema, deformity or clubbing of the nails.

**EXTERNAL EVIDENCE OF TRAUMA:**

There is a small abrasion involving the skin of the right ankle. There is no external evidence of significant trauma.

**INCISIONS:**

The body is opened with the usual Y-shaped incision. The skeletal muscle is red, homogeneous and of normal bulk. The peritoneal cavity is without adhesions and the organs are normally situated. The peritoneal surfaces are smooth and glistening. The domes of the diaphragm arch normally. The pleural cavities are without significant fluid or adhesions and the pleural surfaces are smooth and glistening. The mediastinum appears normal without displacement. The pericardial sac is intact and without significant fluid or adhesions.

**HEART:**

**The heart weighs 300 grams (90-380) and is of normal shape and position.** The epicardial surface is smooth and glistening and contains moderate fat. Upon sectioning, the myocardium is firm, tan-brown and homogeneous throughout. The endocardium is smooth and glistening without mural thrombi or thickening. The cardiac chambers are all of normal size and the ventricular walls of normal thickness. The papillary muscles appear normal and the chordae tendineae are thin and delicate. The valves appear normally formed and are soft and delicate. The coronary ostia are patent and the coronary arteries are normal in number and distribution. No calcific atherosclerosis is noted within the coronary artery system. The pulmonary trunk and main pulmonary arteries are free of emboli or atherosclerotic plaques. The aorta is free of significant atherosclerotic change.

**LUNGS:**

**The right lung weighs 710 grams (150-470) and the left lung weighs 730 grams (140-455).** The lungs appear fully expanded. The pleural surfaces are smooth and glistening without blebs or nodules. The lungs are composed of the usual lobes and fissures. Upon sectioning, the lung parenchyma exhibits moderate congestion. No gross lesions are noted. The bronchi contain scant mucus and the bronchial mucosa is gray-tan. The intrapulmonary arterial tree is without emboli or thrombi.

**GASTROINTESTINAL TRACT:**

The serosal surfaces of the stomach, small and large intestine are intact, smooth and glistening. The walls of these organs are pliable and of normal thickness without evidence of rupture or obstruction. The omentum and mesenteric vessels appear normal.

**LIVER:**

**The liver weighs 1190 grams (825-1519).** Its capsule is intact, smooth and glistening. The cut surface reveals a firm tan-brown parenchyma with a normal lobular architecture without appreciable fibrosis, nodularity or other gross lesions. The gallbladder is normal in location and shape and contains moderate bile. The wall is thin and pliable. No stones or other gross lesions are present.

**SPLEEN:**

**The spleen weighs 110 grams (70-150).** Its capsule is intact, smooth and glistening. The cut surface reveals a soft dark red parenchyma with normally sized Malpighian corpuscles and no gross lesions.

**KIDNEYS:**

**The right kidney weighs 120 grams (40-140) and the left kidney weighs 150 grams (50-155).** The kidneys appear pale. The capsules appear normal stripping with ease. Upon sectioning, the cortices are tan-brown with a distinct corticomedullary junction. No gross lesions are seen.

**Patient Name:** GATLIN, Baylee Ybarra

**Accession #:**

A17-000266

There is stool tinged with blood consistent with a gastrointestinal bleed.

GAW/ima 05/31/2017



## Case Name:

Gatlin,

TOXICOLOGY NUMBER: CVT-17-5973

## Specimen Description:

Baylee  
Hospital samples: 7 ml blood (4 vials) each labeled "Doe, Jane; 05-28-17; 0235 hrs; 372055; Gatlin, Baylee; DOB 03/11/99; 05/28/17; 0259 hrs" Postmortem samples: 13.5 ml subclavian blood (1 gray top vial & 1 green cap vial) & 3.5 ml vitreous humor each labeled "Gatlin, Baylee; SLOSO; #18091; SLO; 5/31/17; 0930 hrs; R Linn #1243"

Delivered by Tricor

Date

02-Jun-17

Received by

Bill Posey

Date

02-Jun-17

Request: Complete Drug Screen

Agency Case # 18091

## Requesting Agency

S.L.O. Co. Sheriff's Office  
Attn: Coroner's Division  
835 Aerovista PL, Ste. 130  
San Luis Obispo CA 93401

## Report To

S.L.O. Co. Sheriff's Office  
Attn: Coroner's Division  
835 Aerovista PL, Ste. 130  
San Luis Obispo CA 93401

## RESULTS

Specimen: Hospital Blood (Lavender Top Vial and Blue Top Vial) and Vitreous Humor Samples

Complete Drug Screen: Lidocaine detected. Specific drug assay for Bath Salts, GHB, LSD, Psilocin, Synthetic Cannabinoids and U-47700 performed. No other common acidic, neutral or basic drugs detected. No Ethyl Alcohol detected.

-Lysergic Acid Diethylamide (LSD) by LCMS-MS = Positive

-"Bath Salts" by LCMS-TOF = Negative

(Cathinone, Methcathinone, Methylone, Mephedrone, MDPV, and alpha-PVP)

-Gamma-Hydroxybutyrate (GHB) by GCMS = Negative

-Psilocin (metabolite of Psilocybin) and Synthetic Cannabinoids ("Spice") by LCMS-TOF = Negative

-U-47700 by LCMS-TOF = Negative

Buprenorphine = Negative

LSD in Hospital Lavender Top Tube = 0.22 ng/mL

LSD in Hospital Blue Top Tube = 0.47 ng/mL

Lidocaine = 2.65 mg/L

Vitreous Urea Nitrogen = 41 mg/dL

Blood Lidocaine Ranges

Effective Level: (1 - 5 mg/L)

Potentially Toxic: (6 - 10 mg/L)

Blood Lysergic Ranges

Effective Level: (0.5 - 5 ng/mL)

Potentially Toxic: (1 ng/mL)

  
B. L. Posey

June 15, 2017

B.L. POSEY  
S.N. KIMBLE  
Directors

1500 Redwood Road  
Davis, California 95611  
Phone (530) 323-0040  
Fax (530) 323-7500





Ian S. Parkinson  
Sheriff - Coroner

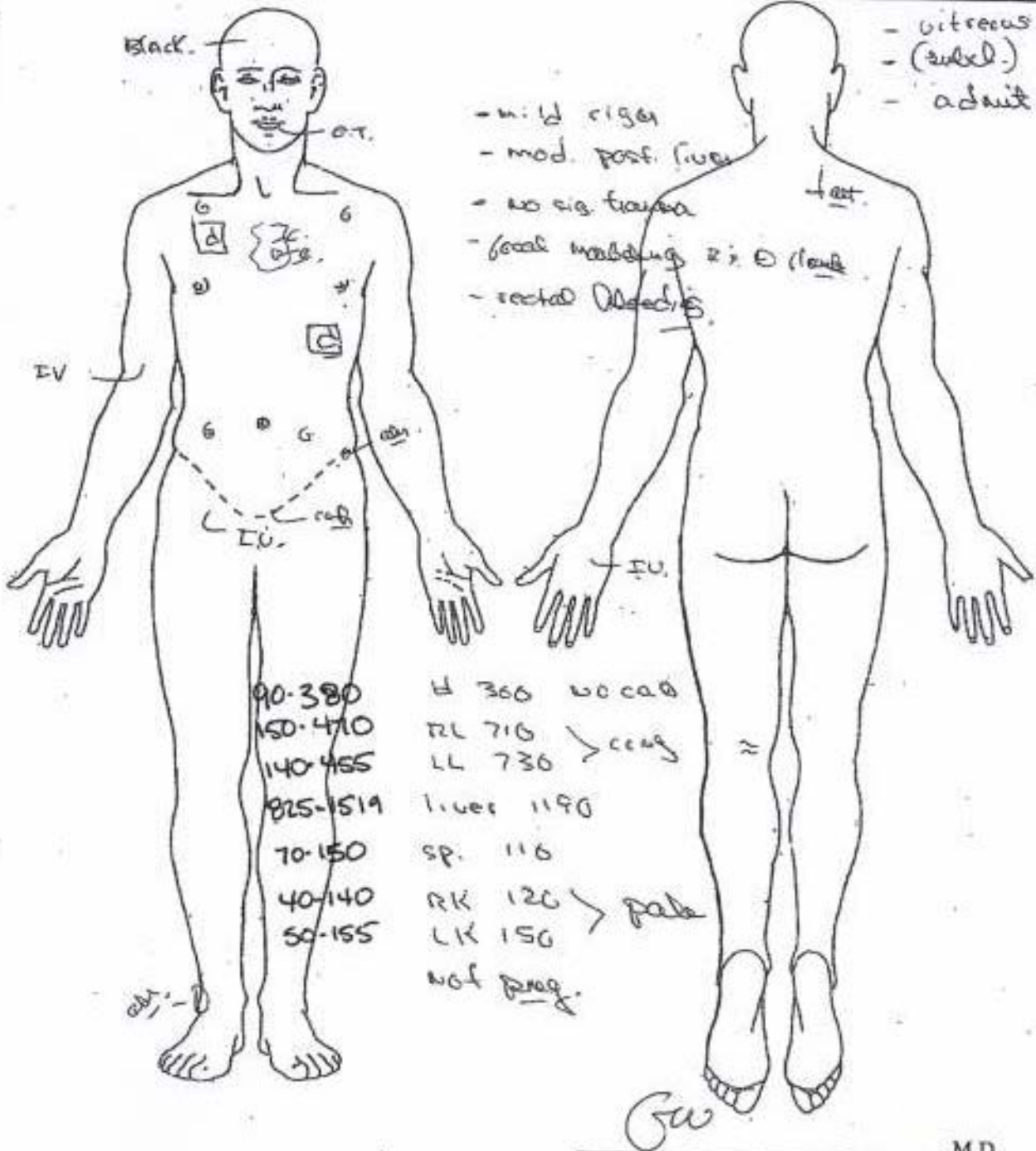
50: 18091  
San Luis Obispo County Sheriff-Coroner's Office

835 Aerovista Pl • Suite 130 • San Luis Obispo • California • 93401

www.slosheriff.org

S. 31.17 0930

Baylee Ybarra Gatlin - 26  
DOB: 5-28-17 0342  
Roxey Linn



M.D.

**Case Name:**

Gatlin,

**TOXICOLOGY NUMBER:** CVT-17-5973**Specimen Description:**

Baylee  
Hospital samples: 7 ml blood (4 vials) each labeled "Doe, Jane; 05-28-17; 0235 hrs; 372055; Gatlin, Baylee; DOB 03/11/99; 05/28/17; 0259 hrs" Postmortem samples: 13.5 ml subclavian blood (1 gray top vial & 1 green cap vial) & 3.5 ml vitreous humor each labeled "Gatlin, Baylee; SLOSO; #18091; SLO; 5/31/17; 0930 hrs; R Linn #1243"

**Delivered by** Tricor**Date** 02-Jun-17**Received by** Bill Posey**Date** 02-Jun-17**Request:** Complete Drug Screen**Agency Case #** 18091**Requesting Agency**

S.L.O. Co. Sheriff's Office  
Attn: Coroner's Division  
835 Aerovista Pl., Ste. 130  
San Luis Obispo CA 93401

**Report To**

S.L.O. Co. Sheriff's Office  
Attn: Coroner's Division  
835 Aerovista Pl., Ste. 130  
San Luis Obispo CA 93401

**RESULTS**

Specimen: Hospital Blood (Lavender Top Vial and Blue Top Vial) and Vitreous Humor Samples

Complete Drug Screen: Lidocaine detected. Specific drug assay for Bath Salts, GHB, LSD, Psilocin, Synthetic Cannabinoids and U-47700 performed. No other common acidic, neutral or basic drugs detected. No Ethyl Alcohol detected.

-Lysergic Acid Diethylamide (LSD) by LCMS-MS = Positive

- "Bath Salts" by LCMS-TOF = Negative

(Cathinone, Methcathinone, Methylone, Mephedrone, MDPV, and alpha-PVP)

-Gamma-Hydroxybutyrate (GHB) by GCMS = Negative

-Psilocin (metabolite of Psilocybin) and Synthetic Cannabinoids ("Spice") by LCMS-TOF = Negative

-U-47700 by LCMS-TOF = Negative

Buprenorphine = Negative

LSD in Hospital Lavender Top Tube = 0.22 ng/mL

Lidocaine = 2.65 mg/L

LSD in Hospital Blue Top Tube = 0.47 ng/mL

Vitreous Urea Nitrogen = 41 mg/dL

**Blood Lidocaine Ranges**


Effective Level: (1 - 5 mg/L)

Potentially Toxic: (6 - 10 mg/L)

**Blood Lysergic Ranges**

Effective Level: (0.5 - 5 ng/mL)

Potentially Toxic: (1 ng/mL)

  
B. L. Posey

June 15, 2017

**B.L. POSEY**  
**S.N. KIMBLE**  
Directors

1580 Tehouse Road  
Clovis, California 93611  
Phone (559) 323-8940  
Fax (559) 323-7502

**Case Name:**  
Gatlin,

**TOXICOLOGY NUMBER:** CVT-17-5949

**Specimen Description:** Baylee  
One (1) vial containing unknown material in a sealed evidence bag labeled "San Luis Obispo County Sheriff; 170504424; 10; Coroner; 05/28/2017; 1; Possible Narcotic Gummies (3); SLSO1243-Linn, Rory; Evidence; E; Drugs/Narcotics"

**Delivered by** GSO

**Date** 01-Jun-17

**Received by** Bill Posey

**Date** 01-Jun-17

**Request:** Substance ID

**Agency Case #** 170504424

**Requesting Agency**

S.L.O. Co. Sheriff's Office  
Attn: Coroner's Division  
835 Aerovista Pl., Ste. 130  
San Luis Obispo CA 93401

**Report To**


S.L.O. Co. Sheriff's Office  
Attn: Coroner's Division  
835 Aerovista Pl., Ste. 130  
San Luis Obispo CA 93401

**Specimen:** Unkown Edible (Gummie) Sample

**RESULTS**

**Substance Identification:**

Description of Material	Identification of Substance	Detection/Confirmation of Substance
Red Gummie Material	Lysergic Acid Diethylamide (LSD)	Detected by LCMS Confirmed by LC-QQQ

  
B. L. Posey

June 16, 2017

**B.L. POSEY**  
**S.N. KIMBLE**  
Directors

1580 Tollhouse Road  
Clovis, California 93611  
Phone (559) 323-9940  
Fax (559) 323-7502